

Original Article

Frequency & Pattern of complications after Parotid Surgery at Tertiary Care Hospital

**Alam MM,¹ Fakir MYA,² Sakender MS,³ Khanam M,⁴ Samad S,⁵ Alam MF,⁶ Jaman MH⁷*

Abstract

Background: Parotid surgery is a common surgical practice in otolaryngology. Different types of parotid surgeries such as superficial parotidectomy, total conservative parotidectomy, total radical parotidectomy or extended radical parotidectomy are performed for both benign and malignant parotid tumour. Surgery of the parotid gland is challenging because of the VII cranial nerve, which enters the gland and branches out inside the gland. Therefore, facial nerve injury is a significant complication after parotid surgery. Other post-operative complications include Frey's syndrome, wound infection, salivary gland fistula, hemorrhage, hematoma, cosmetic deformity, and numbness around the ear. **Aim:** To evaluate the frequency and pattern of complications after different types of parotid surgery at a tertiary care hospital in Bangladesh. **Methods:** This prospective observational cross-sectional study was conducted in the Department of Otolaryngology, Dhaka Medical College & Hospital, Dhaka, for six (6) months from 8th April 2019 to 7th October 2019, with 50 patients who underwent different types of parotid surgery for different indications. The patient's physical condition, different presentation, course of management, outcome of treatment modalities, and subsequent follow-up during the hospital stay were recorded and analyzed. **Result:** The main indication for parotid surgery was pleomorphic adenoma (56%), followed by Warthin Tumors (18.0%), Mucoepidermoid carcinoma (12%), and Squamous cell carcinoma (6%). In this study, 74% of patients developed some complications. Among these, facial nerve paralysis was the most common (44%) complication, followed by hemorrhage or hematoma in 14% of patients, cosmetic deformity in 8.0% of patients, and skin flap necrosis in 6.0% of patients. **Conclusion:** Parotid surgery, while often necessary for the treatment of various parotid gland disorders, is not without its potential complications. These can include facial nerve injury, Frey's syndrome, and salivary fistulae. The procedure has notable risks associated with Hematoma, infection, and scarring. Understanding these complications is crucial for the surgeon and the patient to ensure thorough preoperative planning, informed consent, and meticulous postoperative care. By recognizing and addressing these potential issues promptly, the outcomes of parotid surgery can be significantly improved, enhancing patient satisfaction and overall health.

Keywords: Parotid surgery, pleomorphic adenoma, Warthin's tumour, mucoepidermoid carcinoma, facial nerve palsy, Frey's syndrome, salivary gland fistula.

Received on: 31st July'24. **Accepted on:** 23rd Aug'24

Author's Affiliation:

1. *Md. Mahbub Alam, Resident surgeon, Dept. of ENT & HNS, Shaheed Suhrawardy Medical College Hospital.
2. Md. Abu Yusuf Fakir, Professor, Dept. of ENT & HNS, Shaheed Suhrawardy Medical College Hospital.
3. Md. Sha Sakender, Registrar, Dept. of ENT & HNS, Shaheed Suhrawardy Medical College Hospital.
4. Mohosana Khanam, Junior Consultant, Dhaka Medical College
5. Sazzad Samad, Assistant Professor, Dept. of Otolaryngology & HNS, Dhaka Medical College
6. Md. Fakhrul Alam, Associate Professor and Head, Dept. of Otolaryngology & HNS, ZHSWMC
7. Md. Hasan Jaman, Assistant Registrar, Dept. of ENT, Colonel Malek Medical College.

Address of Correspondence: *Dr. Md. Mahbub Alam, Resident Surgeon, Dept. of ENT & Head-Neck Surgery, Shaheed Suhrawardy Medical College Hospital, Cell: +8801725086208, e-mail: drtuhi35@gmail.com

Introduction:

Parotidectomy is a standard surgical procedure in everyday otolaryngology practice, performed for a wide array of benign and malignant parotid tumors. The most frequent reasons for parotidectomy are pleomorphic adenoma and metastatic cutaneous squamous cell carcinoma.¹

The parotid gland has the highest rate of tumor association among salivary glands, accounting for 64% to 80% of primary epithelial salivary gland tumors.² Approximately 80% of Parotid tumors are benign; the most common histological subtype is pleomorphic adenoma. Other common histological subtypes are Warthin's tumor and basal cell adenomas.³ Surgical removal of the gland is the first-line treatment for all parotid tumors (benign and malignant). Many surgical approaches have been described to expose the deep parenchyma and allow safe and appropriate removal of a tumor, usually by performing an extracapsular dissection (ECD).⁴ A transoral approach is limited to small and benign lesions.⁵ A transcervical approach (TCA) (without mandibulotomy) is correlated with lower morbidity,⁶ but cannot be performed in all patients, especially in patients with large tumors, inferior exposure, or malignancy. The transoral robotic surgery (TORS) approach is an exciting and new technique; the experience of O'Malley and colleagues has confirmed the safety and feasibility of a TORS approach for PPS tumors regarding local control and the low surgical complication rate.⁷

The parotid gland is intimately integrated with the facial nerve. The main risk of parotidectomy is facial nerve paralysis. Apart from facial nerve damage, other common complications associated with parotidectomy are fistula formation, Frey's syndrome, infection, first bite syndrome, numbness over the pinna, and sialocele. It can also lead to poor aesthetic results due to severe asymmetry of the face.⁸ The extent of parotidectomy and type of lesion are the most noteworthy predictors for post-operative facial nerve palsy, other contributors being advanced age, size of the tumor, and location of the lesion.⁹ The extent of facial nerve damage also affects the surgery duration and the surgeon's expertise, although its role as a significant risk factor remains debatable.¹⁰

Due to the variety of sensitive structures overlying,

surrounding, and coursing through the parotid gland, the treating surgeon must implement exquisite care and dexterity to preserve function and avoid unwanted complications. Despite contemporary refinements in techniques, even surgery for benign parotid tumors has a reasonably high rate of complications. The overall morbidity after parotidectomy has been addressed in only a few studies with a limited number of patients.¹¹

Materials and Method:

This observational cross-sectional study was conducted in the Department of Otolaryngology, Dhaka Medical College & Hospital, Dhaka, for six (6) months from 8th April 2019 to 7th October 2019, with 50 patients who underwent different types of parotid surgery for different indications. Following the inclusion and exclusion criteria, this study included the patients. After the selection of the patient, each subject was explained in the study's nature, purpose, and benefit. They were encouraged to participate and Written consent was obtained. They were allowed to withdraw from the study whenever they felt like it. The Institutional Review Board (IRB) of Dhaka Medical College provide Ethical clearance. All the information was recorded and analyzed based on the patient's physical condition, different presentation, course of management, outcome of treatment modalities, and subsequent follow-up during the hospital stay.

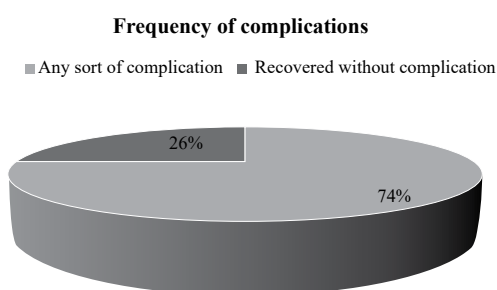
Results:

In this series, the maximum number of patients, 22(44.0%), were between the 31-45 age group, and the next 15(30.0%) were between of 46-60 years. The mean age of the patient was 37.05 ± 9.32 years. Out of 50 study cases 34(68.0%) patients were male and 16(32.0%) were female. Male – female ratio was 2.1:1. The prevalence of parotid tumors was higher in the young age group. More female was affected in elderly age. Among the study population, many respondents were housewives (26.0%), followed by workers (24.0%). A considerable portion of the respondents (20.0%) were farmers. Large numbers of respondents came from urban areas (64.0%), followed by rural areas (36.0%). Pleomorphic adenoma was detected in 56% of patients, Warthin Tumors in 18.0% of patients, Mucoepidermoid carcinoma in 12% of patients, and Squamous cell carcinoma in 6%.

Table 1: Post-operative complications wise distribution of respondents

Postoperative complications	Number of patients	Percentage (%)
Facial nerve paralysis	22	44.0
Temporarily	20	40.0
Permanent	2	4.0
Branch of facial nerve affected		
Marginal mandibular	4	8.0
Buccal+ mandibular	2	4.0
Buccal+ mandibular+cervical	3	6.0
Buccal+ Mandibular+zygomaticotemporal	2	4.0
Mandibular+ Zygomaticotemporal	3	6.0
All branches	8	16.0
Haemorrhage or haematoma	7	14.0
Infection	0	0
Skin flap necrosis	3	6.0
Cosmetic deformity	4	8.0
Parotid fistula	0	0
Facial sinkinesis after facial palsy	5	10.0
Hypoesthesia of greater auricular nerve	1	2.0
Soft tissue deficit	2	4.0
Hypertrophic scar or keloid	1	2.0
Frey's syndrome	1	2.0

Table 1 showed the postoperative complications after surgical management of parotid tumour. Facial nerve paralysis was common complication, noted in 44 % patients, followed by haemorrhage or haematoma in 14% patients, cosmetic deformity in 8.0% patients and skin flap necrosis in 6.0% of patients. It was evident from this study that, 37(74%) of patients developed any sort of complication after parotid surgery.

**Fig 1: Pie chart showing Frequency of Complication**

Discussion:

The present study was undertaken to evaluate the frequency and pattern of complications after parotid surgery. In this study, the maximum number

of patients 22(44.0%) were between the 31-45 age group, and the mean age of the patient was 37.05 ± 9.32 years. Out of 50 cases 34(68.0%) of patients were male and 16(32.0%) were female. Male–female ratio was 2.1:1.

Consistent findings are taken with the results of other studies. In the previous study,¹² 130 (49.84%) were male, and 131 (50.19%) were female, with a male-female ratio 1:0.99. The age ranged from 10 to 70 years, with a mean age of 40.78. 193 benign and 68 malignant salivary gland tumors were found, with the benign-malignant ratio being 2.8:1. The Peak incidence of benign tumors was in the fourth decade (40.5 years). It was observed that both males and females were frequently affected during this age. Another study shows that the overall study population comprised 293 males and 247 females. Overall, 470 (87%) masses were benign, and 70 were malignant. In the “benign” group, the median age at diagnosis was 49 years (range 4-94 years); in the group of malignancies, the median age at diagnosis was 60 years (range 19-94 years).¹³

On the evaluation of diagnosis of parotid swelling, Pleomorphic adenoma was detected in 56% of patients, Warthin Tumors in 18.0% of patients, Mucoepidermoid carcinoma was in 12% of patients, and Squamous cell carcinoma in 6% of patients. Findings are consistent with the results of other studies. A previous study reported that benign salivary gland tumors constitute 73.94% of all tumors in our study. Pleomorphic adenoma (72%) and Warthin's tumor (10.88%) were the 1st and second most common benign tumors. The percentage of benign salivary gland tumors was 73.94%, and malignant salivary gland tumors was 26.05%. The parotid gland was the most common site of origin of benign and malignant salivary gland tumors. Histopathologically, pleomorphic adenoma was the most common benign salivary gland tumor, and mucoepidermoid carcinoma was the most frequent malignant neoplasm. In another study, among the benign lesions, the most frequent, by far, were pleomorphic adenomas (almost 50%) and warthin's tumors (almost 40%).¹³

Teh et al. demonstrated that pleomorphic adenomas, commonly called benign mixed tumors (BMTs), are the most common salivary gland tumors (70% to 80%). Initially presenting as a slow-growing, painless cheek mass, these neoplasms typically appear in middle-aged females aged 30 to 60. They are mixed tumors comprised of epithelial and

myoepithelial cells. On USG, the appearance of BMT is a homogeneous hypoechoic, well-circumscribed mass. Warthin Tumors is the second most common benign salivary gland tumor, accounting for 10% of parotid tumors. They present with painless swelling, with 20% of lesions appearing multifocal (unilateral or bilateral). Warthin tumors are classically seen in older men in the sixth decade of life.¹⁴

It was evident from this study is 37(74%) of patients developed any sort of complication. Study shows that facial nerve paralysis was a common complication, noted in 44 % of patients, followed by hemorrhage or hematoma in 14% of patients, cosmetic deformity in 8.0% of patients, and skin flap necrosis in 6.0% of patients. Although several reports have documented the surgical technique and the oncological outcome achieved with parotidectomy, only a few have described the complications of parotid gland surgery and their management. Post-operative facial nerve dysfunction involving some or all of the nerve branches is the most frequent early complication of parotid gland surgery.⁸

Temporary facial nerve paresis, involving all or just one or two branches of the facial nerve, and permanent total paralysis have occurred, respectively, in 9.3% to 64.6% and 0% to 8% of parotidectomies reported in the literature. The transient facial nerve paresis cases generally resolved within 6 months, with 90% within 1 month.¹⁵ Temporary paresis usually resolves, according to Laccourreye, within the 18th post-operative month. The incidence of facial nerve paralysis is higher with total than with superficial parotidectomy, which may be related to stretch injury or as a result of surgical interference with the vasa nervorum. Revision parotidectomy or parotidectomies for parotid fistula are generally associated with a higher incidence of facial weakness. The branch of the facial nerve most at risk for injury during parotidectomy is the marginal mandibular branch. Facial nerve injury appears more susceptible among older patients. Temporary facial nerve weakness is a cosmetic problem; patients should be told their appearance will return to normal. However, eye protection must be ensured. If facial paresis causes incomplete eye closure, the patient must be advised to use ophthalmic moisture drops frequently during the day and an ophthalmic ointment and eye protection at night. Regular follow-up with an ophthalmologist is mandatory.¹⁶

The “surgical depression” caused by removing the parotid gland is most noticeable immediately

after the operation, when the surrounding skin is slightly oedematous, enhancing the contrast.¹⁷ This depression also decreases with time but does not disappear entirely. The magnitude of this depression depends on the number of glands removed. A superiorly or inferiorly-based sternomastoid flap has been proposed to reconstruct the hollow cavity after parotidectomy. Though the transposition of a sternomastoid muscle flap can, without doubt, Albeit, one should be aware that, improve the facial contour or symmetry of the parotid region, it also creates a ‘donor’ – site hollow deformity or asymmetry of the upper neck, especially in slim patients.¹⁸

Skin-flap necrosis is rare and usually located in the distal tip of the post-auricular skin flap, mainly when a modified rhytidectomy incision has been used. Care must be taken when designing the parotid flap to avoid curving too far posteriorly to avoid this complication.¹⁹ Other parotidectomy complications are keloid and hypertrophic scar. Scar revision with steroid injections may sometimes be necessary. Hemorrhage or hematoma after parotidectomy is uncommon and is usually related to inadequate hemostasis during the surgical procedure. Treatment consists of hematoma evacuation and controlling the bleeding sites.²⁰ Although these complications are not life-threatening for patients and resolve after treatment, they cause distress and anxiety and hamper the quality of life. Proper evaluation and meticulous surgical technique prevent postoperative complications after parotid surgery.

Conclusion:

The current study concludes that the parotid gland is the most typical site of benign and malignant salivary gland tumors. Pleomorphic adenoma is the most common benign, and mucoepidermoid carcinoma is the most common malignant tumor of parotid glands. Parotid surgery, while often necessary for the treatment of various parotid gland disorders, is not without its potential complications. These can include facial nerve injury, Frey’s syndrome, and salivary fistulae. The procedure has notable risks associated with Hematoma, infection, and scarring. Understanding these complications is crucial for the surgeon and the patient to ensure thorough preoperative planning, informed consent, and meticulous postoperative care. By recognizing and addressing these potential issues promptly, the outcomes of parotid surgery can be significantly improved, enhancing patient satisfaction and overall health.

Funding: No funding sources

Conflict of interest: None declared

References:

1. Bova R, Saylor A, Coman WB. Parotidectomy: Review of treatment and outcomes. *ANZ journal of surgery*. 2004; 74(7):563-8.
2. Gaillard C, Perie S, Susini B, St Guily JL. Facial nerve dysfunction after parotidectomy: the role of local factors. *Laryngoscope*. 2005;115:287-91.
3. Koch M, Zenk J, Iro H. Long-term results of morbidity after parotid gland surgery in benign disease. *The Laryngoscope*. 2010; 120(4):724-30.
4. Dell'Aversana Orabona G, Salzano G, Abbate V, Piombino P, Astarita F, Iaconetta G. Use of the SMAS flap for reconstruction of the parotid lodge. *Acta Otorhinolaryngol Ital*. 2015;35:406-11.
5. Li C, Xu Y, Zhang C, Sun C, Chen Y, Zhao H. Modified partial superficial parotidectomy versus conventional superficial parotidectomy improves treatment of pleomorphic adenoma of the parotid gland. *Am J Surg*. 2014;208:112-8.
6. Quer M, Guntinas-Lichius O, Marchal F, Vander Poorten V, Chevalier D, León X. Classification of parotidectomies: a proposal of the European Salivary Gland Society. *Eur ArchOtorhinolaryngol*. 2016;273:3307-12.
7. de Vicente JC, González-García M, de Villalaín L, Fernández-Valle Á. Modified facelift approach combined with a superficial musculoaponeurotic system flap in the treatment of benign parotid tumors. *J Craniomaxillofac Surg*. 2015;43:1655-61.
8. Guntinas-Lichius O, Gabriel B, Peter Klussmann J. Risk of facial palsy and severe Frey's syndrome after conservative parotidectomy for benign disease: Analysis of 610 operations. *Acta oto-laryngologica*. 2006; 126(10):1104-9.
9. Musani MA, Zafar A, Suhail Z, Malik S, Mirza D. Facial nerve morbidity following surgery for benign parotid tumours. *J Coll Physicians Surg Pak*. 2014; 24(8):569- 72.
10. Witt RL, Rejto L. Pleomorphic adenoma: Extracapsular dissection versus partial superficial parotidectomy with facial nerve dissection. *Delaware medical journal*. 2009; 81(3):119-25.
11. Thahim K, Udaipurwala IH, Kaleem M. Clinical manifestations, treatment outcome and post-operative complications of parotid gland tumours- an experience of 20 cases. *J Pak Med Assoc*. 2013; 63(12):1472-5.
12. Marchese-Ragona R, De Filippis C, Marioni G, Staffieri A. Treatment of complications of parotid gland surgery. *Acta Otorhinolaryngol Ital*. 2005;25:174-8.
13. Gaillard C, Perie S, Susini B, St Guily JL. Facial nerve dysfunction after parotidectomy: the role of local factors. *Laryngoscope*. 2005;115:287-91.
14. Marchesi M, Biffoni M, Trinchì S, Turriziani V, Campana FP. Facial nerve function after parotidectomy for neoplasms with deep localization. *Surg Today*. 2006;36:308-11.
15. Guntinas-Lichius O, Klussmann JP, Schroeder U, Quante G, Jungehuelsing M, Stennert E. Primary parotid malignoma surgery in patients with normal preoperative facial nerve function: outcome and long-term postoperative facial nerve function. *Laryngoscope*. 2004;114:949-56.
16. Upton DC, McNamar JP, Connor NP, Harari PM, Hartig GK. Parotidectomy: ten-year review of 237 cases at a single institution. *Otolaryngol Head Neck Surg*. 2007;136:788-92.
17. Quer M, Vander Poorten V, Takes RP, Silver CE, Boedeker CC, de Bree R. Surgical options in benign parotid tumors: a proposal for classification. *Eur Arch Otorhinolaryngol*. 2017;274:3825-36.
18. Porter MJ, Wood SJ. Preservation of the great auricular nerve during parotidectomy. *Clin Otolaryngol Allied Sci*. 1997;22:251-3.
19. Becelli R, Morello R, Renzi G, Matarazzo G. Great auricular nerve preservation during parotidectomy for benign tumors. *J Craniofac Surg*. 2014;25:422-4.
20. Min HJ, Lee HS, Lee YS, Jeong JH, Cho SH, Lee SH. Is it necessary to preserve the posterior branch of the great auricular nerve in parotidectomy? *Otolaryngol Head Neck Surg*. 2007;137:636-41